

REVIEW

Iliopsoas abscesses

I H Mallick, M H Thoufeeq, T P Rajendran

Postgrad Med J 2004;80:459-462. doi: 10.1136/pgmj.2003.017665

Iliopsoas abscess is a relatively uncommon condition that can present with vague clinical features. Its insidious onset and occult characteristics can cause diagnostic delays, resulting in high mortality and morbidity. The epidemiology, aetiology, clinical features, and management of iliopsoas abscess are discussed.

Antibiotics were continued for a week. The pus grew *Escherichia coli* and the histology of the specimen was confirmed as Crohn's disease. A month later he presented with a recurrent iliopsoas abscess, which was drained surgically. The ureteric stent was removed two months after its insertion. A repeat IVU was normal with no hold-up of contrast. Two years on, he is doing well without any further complications.

Before the discovery of modern antituberculous treatment iliopsoas abscess was characteristically a well recognised complication of tuberculosis of the spine. However with the decreasing prevalence of tuberculosis, iliopsoas abscess is becoming uncommon in the developed countries. Iliopsoas abscess is a collection of pus in the iliopsoas compartment. Iliopsoas abscess was first described by Mynter in 1881 who referred to this as psioitis.¹

ILLUSTRATIVE CASE HISTORY

A previously well 40 year old man presented with a two day history of right loin to groin pain and nausea. He denied any dysuria, fever, or chills. Physical examination was unremarkable except for moderate tenderness in the right loin on pressure. Urine dipstix was 1+ positive for blood, however urine microscopy was normal. His white cell count was raised at $14.0 \times 10^9/l$.

A plain radiograph of the kidney ureter bladder did not show any evidence of a calculus. An ultrasound scan of the abdomen revealed a right hydronephrotic kidney with a right hydro-ureter. No definite renal calculus was seen. An intravenous urogram (IVU) was performed which confirmed the ultrasound findings (fig 1). The pain settled down and it was assumed that the stone had been passed. He was discharged home on analgesics with a follow up appointment. One week later he was seen again urgently with similar pain. Cystoscopy with right retrograde pyelogram was performed which did not show any obstruction of the renal tracts. Meanwhile his blood haemoglobin dropped to 77 g/l. Three units of red cells were transfused to correct the anaemia. Computed tomography of the abdomen and pelvis was performed which revealed a right iliopsoas abscess (fig 2). Broad spectrum intravenous antibiotics were started and an emergency laparotomy was performed. At operation the distal third of the ileum was found stuck to the right iliopsoas muscle as a mass with abscess formation. The right ureter was found to be adherent to the posterior abdominal wall with hydroureter proximally. Ileocaecal resection and drainage of the abscess was performed. A right ureteric stent was also inserted at the same time.

ANATOMY

The iliopsoas compartment is an extraperitoneal space which contains the iliopsoas and iliacus muscles. The psoas major is a long fusiform muscle placed on the side of the lumbar region of the vertebral column and brim of the lesser pelvis (fig 3). It arises from the lateral borders of T12 to the L5 vertebrae. The muscle proceeds downward across the brim of the lesser pelvis and diminishing gradually in size, passes beneath the inguinal ligament and in front of the capsule of the hip joint and ends in a tendon. The tendon receives nearly the whole of the fibres of the iliacus muscle and is inserted into the lesser trochanter of the femur. The psoas major and iliacus are sometimes regarded as a single muscle named the iliopsoas. It is innervated by the branches of L2, 3, and 4, and it is the primary flexor of the hip joint. The psoas muscle lies in close proximity to organs such as the sigmoid colon, appendix, jejunum, ureters, abdominal aorta, kidneys, pancreas, spine, and iliac lymph nodes. Hence infections in these organs can spread to the iliopsoas muscle. The abundant blood supply of the muscle is believed to predispose it to haematogenous spread from occult sites of infection.²

AETIOLOGY

Iliopsoas abscess may be classified as primary or secondary, depending on the presence or absence of underlying disease. Primary iliopsoas abscess occurs probably as a result of haematogenous spread of an infectious process from an occult source in the body. The group of patients in which primary iliopsoas abscess occurs is summarised in box 1.³ Crohn's disease is the commonest cause of secondary iliopsoas abscess.⁴ The other causes of secondary iliopsoas abscesses is summarised in table 1. Patients who have had instrumentations or procedures performed in the groin, lumbar, or hip areas are at a particular risk of developing an iliopsoas abscess.⁵⁻⁷ In a review of 367 cases, Ricci *et al* noted world wide differences in its aetiology.⁸ In Asia and Africa, over 99% of iliopsoas abscess are primary,

Abbreviations: IVU, intravenous urogram; PCD, percutaneous drainage

See end of article for authors' affiliations

Correspondence to:
Mr I H Mallick, University
Department of Surgery,
Royal Free and University
College Medical School,
Hampstead, London NW3
2QG, UK; i.mallick@rfc.
ucl.ac.uk

Submitted
1 December 2003
Accepted
10 February 2004

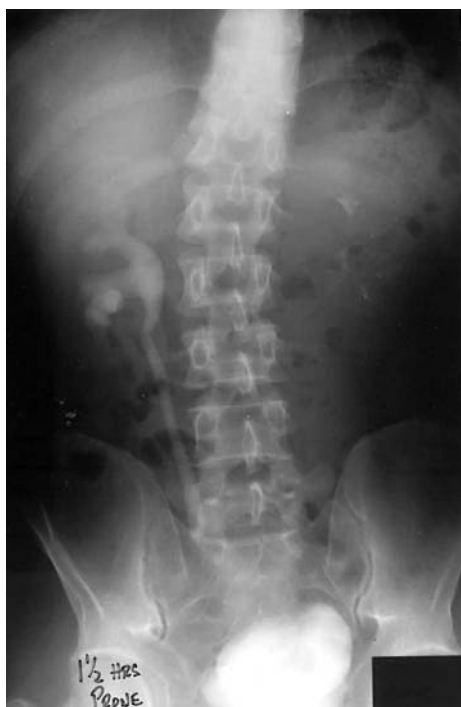

Figure 1 Intravenous urogram showing a dilated right renal pelvis and a dilated ureter. Note the scoliosis of the spine and compression of the right half of the urinary bladder by the abscess.

whereas 17% and 61% are primary in Europe and North America respectively.⁸ Iliopsoas abscess is common in the young compared with the elderly.⁹ It is reported to be commoner in males than females.¹⁰⁻¹¹ Bresee *et al* in a study of 142 paediatric patients with iliopsoas abscess found a 57% occurrence on the right side, 40% on the left side, and 3% had bilateral abscesses.¹² The mortality rate in primary iliopsoas abscess is 2.4% and in secondary abscesses is 19%.¹³ Ricci *et al* suggested that the mortality rate in untreated patients is 100%.⁸

MICROBIOLOGY

Staphylococcus aureus is the causative organism in over 88% of patients with primary iliopsoas abscess.⁸ Secondary iliopsoas abscess is caused by streptococcus species 4.9% and *E coli* 2.8%.⁸ *Mycobacterium tuberculosis* as a cause of iliopsoas abscess is currently uncommon in the western world, but common in the developing countries. The other causative organisms include proteus,⁹ *Pasteurella multocida*,¹⁴ bacteroides,¹⁵ clostridium,¹⁶ *Yersinia enterocolitica*,¹⁷ klebsiella,¹⁸

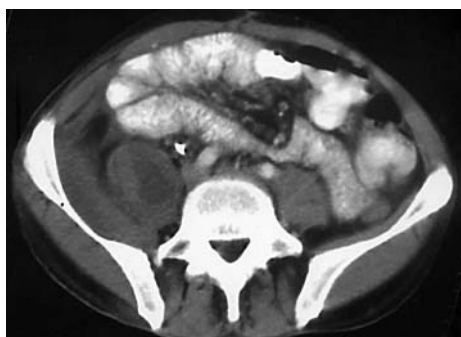

Figure 2 Computed tomogram of the abdomen and pelvis revealing a right psoas abscess.

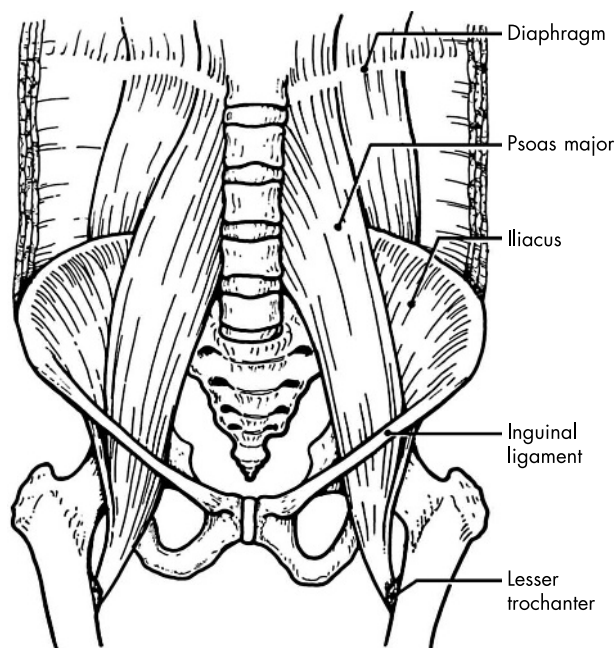


Figure 3 Anatomy of the iliopsoas muscles.

Box 1: Primary iliopsoas abscess can occur in:

- Diabetes mellitus.
- Intravenous drug abuse.
- AIDS.
- Renal failure.
- Immunosuppression.

methicillin resistant *Staphylococcus aureus*,¹⁹ salmonella,²⁰ *Mycobacterium kansasii*,²¹ and *Mycobacterium xenopi*.²²

CLINICAL FEATURES

The clinical presentation of iliopsoas abscess is often variable and non-specific. The classical clinical triad consisting of fever, back pain, and limp is present in only 30% of the patients with iliopsoas abscess.²³ As the psoas muscle is innervated by L2, L3, and L4, pain can radiate to hip and thigh. Other symptoms are vague abdominal pain, malaise, nausea, and weight loss. The clinical features are summarised in box 2.

A diligent physical examination is essential for the prompt diagnosis of this condition. The diagnosis may be obvious if the patient is noted to favour the position of greatest comfort.

Table 1 Conditions associated with secondary iliopsoas abscess

Gastrointestinal	Crohn's disease, diverticulitis, appendicitis, colorectal cancer
Genitourinary	Urinary tract infection, cancer, extracorporeal shock wave lithotripsy
Musculoskeletal	Vertebral osteomyelitis, septic arthritis, infectious, sacroiliitis
Vascular	Infected abdominal aortic aneurysm, femoral vessel, catheterisation
Miscellaneous	Endocarditis, intrauterine contraceptive device, suppurative lymphadenitis

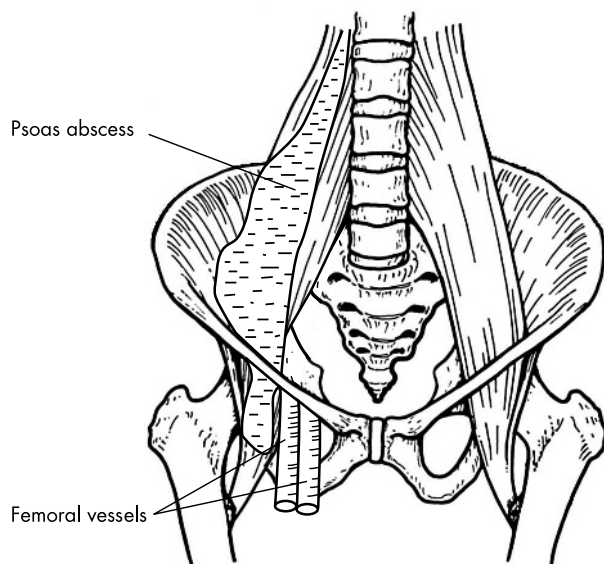


Figure 4 Relationship of iliopsoas abscess to femoral vessels.

This is the supine position with the knee moderately flexed and the hip mildly externally rotated.²⁴ There are well defined signs to elicit in patients with iliopsoas abscess, though they are not very specific of this condition. The principle of these tests is that the psoas muscle is the main flexor of the hip (box 3). Patients may present with a painless swelling below the inguinal ligament (fig 4). This may be confused with a femoral hernia or enlarged inguinal lymph nodes. In this instance, it presents as a reducible swelling with an impulse on coughing. An iliopsoas abscess secondary to Crohn's disease may compress the ureter and present with hydronephrosis (as illustrated in the case history). A large iliopsoas abscess may present with deep venous thrombosis.²⁵ The cause of the thrombosis is due to extrinsic compression of the iliac vein from the iliopsoas abscess.²⁶

Tumours arising from the structures within the pelvis or lumbar area may mimic an iliopsoas abscess.²⁷⁻³¹ A physician attending such a patient must be aware as the treatment is different in these cases.

INVESTIGATIONS

Laboratory investigations may reveal a raised white cell count, raised C-reactive protein, anaemia, and raised erythrocyte sedimentation rate.² Blood cultures may be positive for a particular organism causing the abscess. Initial radiological investigations may include radiography of the kidney ureter bladder, an IVU, or barium enema. These are neither specific or sensitive and are unhelpful in the diagnosis of iliopsoas abscess. Sometimes gas forming abscesses can be seen as mottled gas shadows in the retroperitoneum.³²⁻³³ Ultrasound is inexpensive, has no radiation effects, and is

Box 2: Clinical features

- Flank/back/abdominal pain.
- Fever.
- Limp.
- Malaise.
- Weight loss.
- Lump in the groin.

Box 3: Tests to elicit iliopsoas inflammation

1. The examiner places his hand just proximal to the patient's ipsilateral knee and the patient is asked to lift his thigh against the examiner's hand. This will cause contraction of the psoas and results in pain.
2. With the patient lying on the normal side, hyperextension of the affected hip results in pain as the psoas muscle is stretched.

NB: These tests may be positive in appendicitis in which there is inflammation of the iliopsoas without the formation of iliopsoas abscess.

easy to perform but is extremely operator dependent. Ultrasound is diagnostic in only 60% of the cases.⁸⁻³³ The retroperitoneal space can be difficult to visualise ultrasonically and can be obscured by bowel gas.³⁴ Computed tomography should be done for definitive diagnosis and is considered the "gold standard".¹¹ Some authors believe that magnetic resonance imaging is superior to computed tomography because of better discrimination of soft tissues and the ability to visualise the abscess wall and the surrounding structures without the need of a intravenous contrast medium.¹³⁻³⁵

MANAGEMENT

Treatment involves the use of appropriate antibiotics along with drainage of the abscess. An adequate knowledge of the causative organisms should guide the initial choice of antibiotics. Depending on the results of the abscess fluid culture and sensitivity, adjustments should be made. In patients suspected to have primary iliopsoas abscess, anti-staphylococcal antibiotics should be started before the culture results.⁹ In secondary iliopsoas abscess it is wise to start patients on broad spectrum antibiotics like clindamycin, antistaphylococcal penicillin, and an aminoglycoside.¹² Drainage of the abscess may be done through computed tomography guided percutaneous drainage (PCD) or surgical drainage. PCD is much less invasive and has been proposed as the draining method of choice.³⁶⁻³⁸ Mueller *et al* reported first application of PCD in iliopsoas abscesses in 1984.³⁹ In a study of 22 patients of whom 20 patients had primary and two had secondary iliopsoas abscesses, Cantasdemir *et al* found that PCD was effective in 21 out of the 22 patients.⁴⁰ This procedure is associated with a low morbidity and mortality. The indications of operation are (a) failure of PCD, (b) relative contraindication of PCD, for example, clotting disorders, and (c) the presence of another intra-abdominal pathology which requires surgery. In patients with Crohn's disease, performing a single operation to drain the abscess and resect the diseased bowel is desirable.⁴¹ Sometimes PCD can be a useful initial treatment to improve the patient's condition before surgery.⁴² Antibiotics are sometimes continued up to two weeks after complete abscess drainage.

CONCLUSION

It is prudent that this condition is recognised and managed promptly. Early management and drainage of the abscess reduces the morbidity and mortality.

Authors' affiliations

I H Mallick, University Department of Surgery, Royal Free and University College Medical School, Hampstead, London, UK

M H Thoufeeq, General Medicine, Peterborough District General Hospital, Peterborough, Cambridgeshire, UK

T P Rajendran, Diana Princess of Wales Hospital, Grimsby, Lincolnshire, UK

REFERENCES

- 1 Mynter H. Acute psoitis. *Buffalo Med Surg J* 1881;**21**:202–10.
- 2 Taiwo B. Psoas abscess: a primer for the internist. *South Med J* 2001;**94**:2–5.
- 3 Walsh TR, Reilly JR, Hanley E, et al. Changing etiology of iliopsoas abscess. *Am J Surg* 1992;**163**:413–16.
- 4 Agrawal SN, Dwivedi AJ, Khan M. Primary psoas abscess. *Dig Dis Sci* 2002;**47**:2103–5.
- 5 Buttaro M, Gonzalez DV, Piccaluga F. Psoas abscess associated with infected total hip arthroplasty. *J Arthroplasty* 2002;**17**:230–4.
- 6 Korovessis P, Petsinis G, Papazisis Z. Unilateral psoas abscess following posterior transpedicular stabilization of the lumbar spine. *Eur Spine J* 2000;**9**:588–90.
- 7 Lee BB, Kee WD, Griffith JF. Vertebral osteomyelitis and psoas abscess occurring after obstetric epidural anesthesia. *Reg Anesth Pain Med* 2002;**27**:220–4.
- 8 Ricci MA, Rose FB, Meyer KK. Pyogenic psoas abscess: worldwide variations in etiology. *World J Surg* 1986;**10**:834–43.
- 9 Gruenwald I, Abrahamson J, Cohen O. Psoas abscess: case report and review of the literature. *J Urol* 1992;**147**:1624–6.
- 10 Paley M, Sidhu PS, Evans RA, et al. Retroperitoneal collections—etiology and radiological implications. *Clin Radiol* 1997;**52**:290–4.
- 11 Zissin R, Gayer G, Kots E, et al. Iliopsoas abscess: a report of 24 patients diagnosed by CT. *Abdom Imaging* 2001;**26**:533–9.
- 12 Bresee JS, Edwards MS. Psoas abscess in children. *Pediatr Infect Dis J* 1990;**9**:201–6.
- 13 Qureshi NH, O'Brien DP, Allcutt DA. Psoas abscess secondary to discitis: a case report of conservative management. *J Spinal Disord* 2000;**13**:73–6.
- 14 Steiner FT, Brem AS, Peter G. Psoas muscle abscess due to *Pasteurella multocida*. *J Urol* 1987;**137**:487–8.
- 15 Melissas J, Romanos J, de Bree E, et al. Primary psoas abscess. Report of three cases. *Acta Chir Belg* 2002;**102**:114–17.
- 16 Wells AD, Fletcher MS, Teare EL, et al. Clostridial myositis of the psoas complicating percutaneous nephrostomy. *Br J Surg* 1985;**72**:582.
- 17 Kahn FW, Glasser JE, Agger WA. Psoas muscle abscess due to *Yersinia enterocolitica*. *Am J Med* 1984;**76**:947–9.
- 18 Chang CM, Ko WC, Lee HC, et al. Klebsiella pneumoniae psoas abscess: predominance in diabetic patients and grave prognosis in gas-forming cases. *J Microbiol Immunol Infect* 2001;**34**:201–6.
- 19 Madden BP, Datta S, Planche T. Pyogenic psoas abscess: a rare complication after orthotopic heart transplantation. *J Heart Lung Transplant* 2002;**21**:928–31.
- 20 Kindo AJ, Mathew R, Ravi A, et al. Rare co-existence of *Salmonella typhi* and mycobacteria tuberculosis in a psoas abscess—a case report. *Indian J Pathol Microbiol* 2001;**44**:493–4.
- 21 Simms V, Musher DM. Psoas muscle abscess due to *Mycobacterium kansasii* in an apparently immunocompetent adult. *Clin Infect Dis* 1998;**27**:893–4.
- 22 Prigogine T, Stoffels G, Fauville-Dufaux M, et al. Primary psoas muscle abscess due to *Mycobacterium xenopi*. *Clin Infect Dis* 1998;**26**:221–2.
- 23 Chern CH, Hu SC, Kao WF, et al. Psoas abscess: making an early diagnosis in the ED. *Am J Emerg Med* 1997;**15**:83–8.
- 24 Wong JG. The psoas signs. Well-described but often forgotten physical examination findings of iliopsoas inflammation. *N C Med J* 1993;**54**:598–600.
- 25 Demuren OA, Abomelha M. Psoas abscess presenting with femoro-popliteal vein thrombosis. *Saudi Med J* 2002;**23**:96–8.
- 26 Arai Y, Kawakami T, Soga H, et al. Psoas abscess associated with iliac vein thrombosis and piriformis and gluteal abscesses. *Int J Urol* 1999;**6**:257–9.
- 27 Bar-Dayana Y, Fishman A, Levi Z, et al. Squamous cell carcinoma of the cervix with psoas abscess-like metastasis in an HIV-negative patient. *Isr J Med Sci* 1997;**33**:674–6.
- 28 Devendra K, Tay SK. Metastatic carcinoma of the cervix presenting as a psoas abscess in an HIV-negative woman. *Singapore Med J* 2003;**44**:302–3.
- 29 Kishi Y, Kajiwara S, Seta S, et al. Retroperitoneal schwannoma misdiagnosed as a psoas abscess: report of a case. *Surg Today* 2002;**32**:849–52.
- 30 Masters JG, Cumming JA, Jennings P. Psoas abscess secondary to metastases from transitional cell carcinoma of the bladder. *Br J Urol* 1996;**77**:155–6.
- 31 Nabi G, Dogra PN, Pradeep H. Psoas abscess-like metastasis from transitional cell carcinoma of urinary bladder. *Indian J Cancer* 2002;**39**:78–80.
- 32 Chen CW, Ko WC, Sung JM, et al. Ruptured mycotic aneurysm of the iliac artery complicated by emphysematous psoas muscle abscess: report of two cases. *J Formos Med Assoc* 2002;**101**:144–7.
- 33 Huang JJ, Ruan MK, Lan RR, et al. Acute pyogenic iliopsoas abscess in Taiwan: clinical features, diagnosis, treatments and outcome. *J Infect* 2000;**40**:248–55.
- 34 Gordin F, Stamler C, Mills J. Pyogenic psoas abscesses: noninvasive diagnostic techniques and review of the literature. *Rev Infect Dis* 1983;**5**:1003–11.
- 35 Wu TL, Huang CH, Hwang DY, et al. Primary pyogenic abscess of the psoas muscle. *Int Orthop* 1998;**22**:41–3.
- 36 Dinc H, Onder C, Turhan AU, et al. Percutaneous catheter drainage of tuberculous and nontuberculous psoas abscesses. *Eur J Radiol* 1996;**23**:130–4.
- 37 Gervais DA, Hahn PF, O'Neill MJ, et al. Percutaneous abscess drainage in Crohn disease: technical success and short- and long-term outcomes during 14 years. *Radiology* 2002;**222**:645–51.
- 38 Haaga JR. Imaging intraabdominal abscesses and nonoperative drainage procedures. *World J Surg* 1990;**14**:204–9.
- 39 Mueller PR, Ferrucci JT Jr, Wittenberg J, et al. Iliopsoas abscess: treatment by CT-guided percutaneous catheter drainage. *Am J Roentgenol* 1984;**142**:359–62.
- 40 Cantasdemir M, Kara B, Cebi D, et al. Computed tomography-guided percutaneous catheter drainage of primary and secondary iliopsoas abscesses. *Clin Radiol* 2003;**58**:811–15.
- 41 Procaccino JA, Lavery IC, Fazio VW, et al. Psoas abscess: difficulties encountered. *Dis Colon Rectum* 1991;**34**:784–9.
- 42 Jawhari A, Kamm MA, Ong C, et al. Intra-abdominal and pelvic abscess in Crohn's disease: results of noninvasive and surgical management. *Br J Surg* 1998;**85**:367–71.



Iliopsoas abscesses

I H Mallick, M H Thoufeeq and T P Rajendran

Postgrad Med J 2004 80: 459-462

doi: 10.1136/pgmj.2003.017665

Updated information and services can be found at:

<http://pmj.bmj.com/content/80/946/459.full.html>

These include:

References

This article cites 42 articles, 4 of which can be accessed free at:

<http://pmj.bmj.com/content/80/946/459.full.html#ref-list-1>

Article cited in:

<http://pmj.bmj.com/content/80/946/459.full.html#related-urls>

Email alerting service

Receive free email alerts when new articles cite this article. Sign up in the box at the top right corner of the online article.

Notes

To request permissions go to:

<http://group.bmj.com/group/rights-licensing/permissions>

To order reprints go to:

<http://journals.bmj.com/cgi/reprintform>

To subscribe to BMJ go to:

<http://group.bmj.com/subscribe/>