

Use of this content is subject to the Terms and Conditions

SCIATIC NEUROPATHY

Neurologic Clinics - Volume 17, Issue 3 (August 1999) - Copyright © 1999 W. B. Saunders Company

DOI: 10.1016/S0733-8619%2805%2970155-9

617

ENTRAPMENT AND OTHER FOCAL NEUROPATHIES

SCIATIC NEUROPATHY

Eric C. Yuen ¹ MD

Yuen T. So ² MD, PhD

¹ Department of Neurology, University of Washington, Seattle, Washington (ECY)

² Department of Neurology, Stanford University Medical Center, Stanford, California (YTS)

Address reprint requests to

Eric C. Yuen, MD

Department of Neurology

University of Washington

Box 356115

Seattle, WA 98195

ANATOMY

The sciatic nerve derives its nerve fibers from the L4, L5, S1, and S2 nerve roots. It arises from the lumbosacral plexus and leaves the pelvis through the greater sciatic foramen (sciatic notch) (Fig. 1). It passes over the obturator internus muscle, and beneath the gluteal and the piriformis muscles. As it exits the gluteal compartment, the sciatic nerve runs posterior and medial to the hip joint. The nerve then courses deep in the thigh and posterior to the femur. The nerve consists of two distinct trunks, the lateral (peroneal division) and the medial (tibial division) (Fig. 2). The peroneal and the tibial divisions lie next to each other to form the sciatic nerve. The divisions physically separate from each other at the midthigh to the distal thigh to form the common peroneal and tibial nerves. Occasionally, the divisions separate at the proximal thigh.

Branches coming off the tibial division in the proximal thigh innervate all except one of the hamstring muscles. The exception is the short head of the biceps femoris (BF-SH) supplied by the peroneal division at approximately midthigh level, just before the sciatic nerve divides into the common peroneal and tibial nerves. All muscles below the knee receive innervation from the sciatic nerve, and, except for the saphenous nerve, all sensory nerves are derived from the sciatic nerve.

618

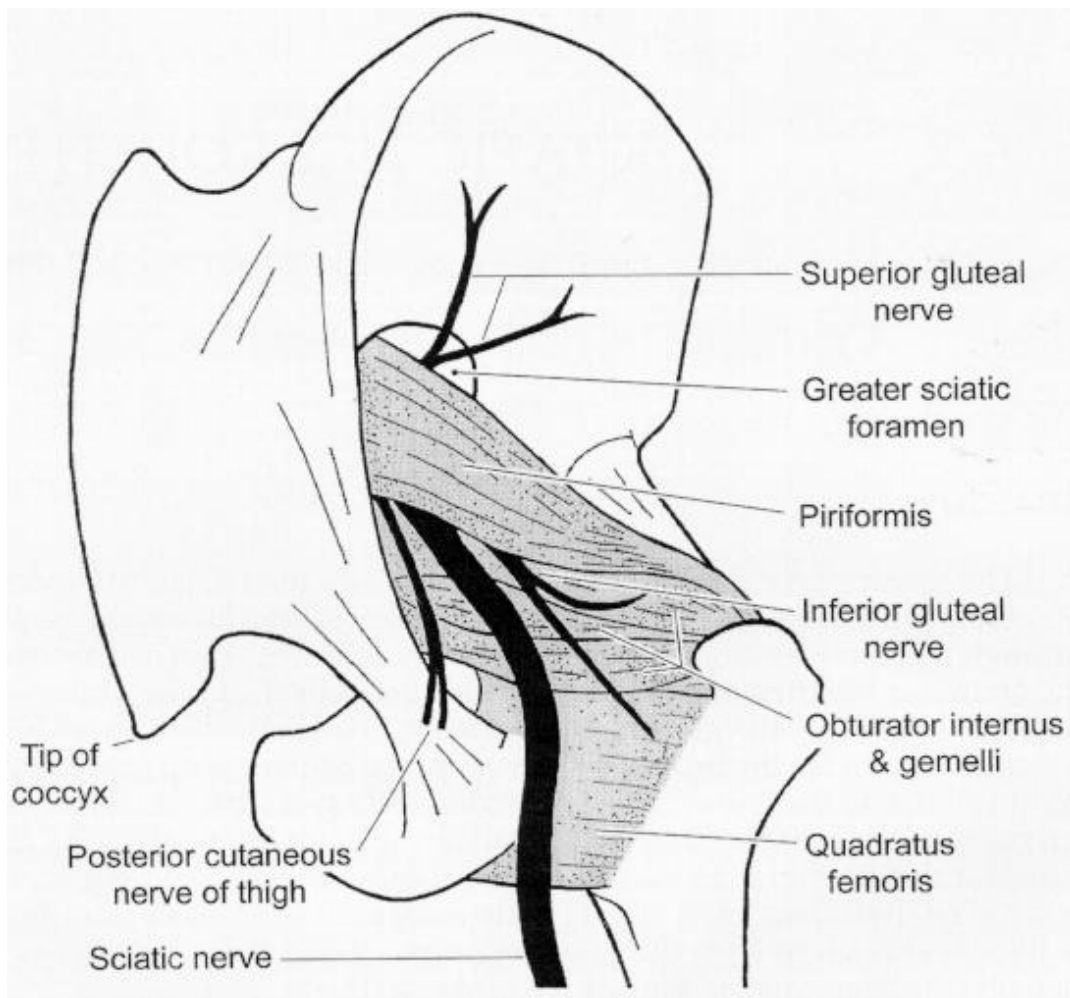


Figure 1. Posterior view of the sciatic nerve as it arises from the lumbosacral plexus, passes through the greater sciatic foramen (sciatic notch), and courses between the piriformis and obturator internus muscles. The overlying gluteal muscles are not shown.

CLINICAL PRESENTATION

Symptoms

Weakness, numbness, and paresthesias are frequent symptoms of sciatic neuropathy. ^[93] Foot drop is usually the most prominent symptom, for two reasons. First, foot drop as a result of tibialis anterior weakness causes greater gait disability compared with other sciatic-innervated muscles. Second, as discussed below, the peroneal-innervated muscles are more severely weak compared with tibial-innervated muscles. Weakness of toe extension or flexion, ankle plantar flexion, eversion, inversion, and knee flexion are other symptoms that result from weakness of sciatic-innervated muscles. A severe sciatic neuropathy can lead to a flail lower leg. Numbness and paresthesias in the sciatic-nerve distribution are also frequent symptoms, depending on the severity of the neuropathy.

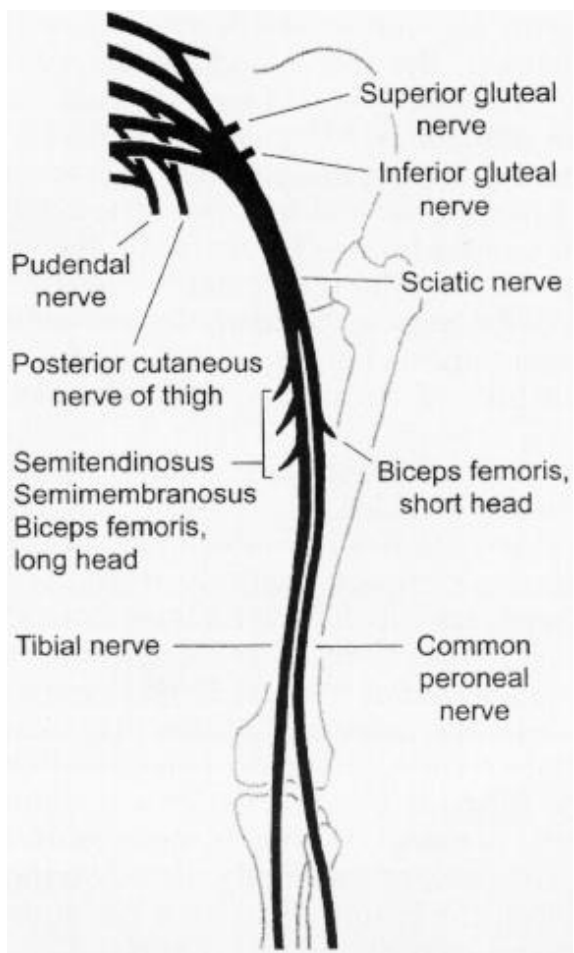


Figure 2. Posterior view of the sciatic nerve, which innervates the hamstring muscles before dividing into the peroneal and tibial nerves. The peroneal and tibial divisions of the sciatic nerve are shown separated; however, the two divisions most often physically separate at distal to mid-thigh.

Dysesthetic pain in the distal sciatic-nerve distribution is a less common but still a frequent complaint, present in 57% of patients in one series.^[93] The pain is commonly described as either a constant burning sensation or a sharp, jabbing pain. The pain can occur immediately with the onset of sciatic neuropathy or can be delayed by weeks to months. When delayed in onset, the pain often begins as motor function improves. Almost all patients who have gunshot wounds or chronic progressive sciatic neuropathy from mass lesions, entrapment, or compression of the sciatic nerve appear to develop pain at some point during their illness. Fortunately, the dysesthetic pain usually does not last for more than a few months and typically responds to pharmacologic treatment.

Signs

Motor, sensory, and reflex deficits in the sciatic-nerve distribution are almost always present in sciatic neuropathy. Ankle reflexes are usually

diminished or absent, depending on the severity of the lesion. As with most mononeuropathies, the motor and the sensory deficits are more prominent distally. Thus, weakness of toe extension and flexion are often the most prominent sign, followed by ankle and plantar dorsiflexion, eversion, and inversion. Hamstring muscle weakness is rarely significant except in the most severe, proximal lesions.^[92] The relative sparing of the hamstrings may be caused by two factors. First, they are the most proximal muscles innervated by the sciatic nerve and thus are reinnervated more quickly than distal muscles. Second, the semitendinosus, semimembranosus, and biceps femoris long head are innervated by the tibial division and form the bulk of the hamstring. As discussed below, the tibial division is often less severely affected than the peroneal division. Thus, most of the hamstring muscles are less severely affected compared with the peroneal-innervated muscles.

Interestingly, many studies have documented greater susceptibility of the peroneal division compared with the tibial division in sciatic neuropathy. * This rule appears to hold true for most causes, especially in those associated with hip replacement. Possible exceptions

include gunshot wounds to the thigh and femur fracture. [27] [40] [94] There are a number of possible explanations why the peroneal division may be more susceptible to injury than the tibial division. [81] First, the peroneal division has larger fascicles that have less supportive connective tissue compared with the tibial division. Second, the peroneal division is more securely fixed at both the sciatic notch and the neck of the fibula, thus leaving it more prone to stretch injuries. Third, the peroneal division lies superficial to the tibial division in the hip and proximal thigh regions.

There have been reports of patients who have involvement of only the peroneal division and complete clinical and electrodiagnostic sparing of the tibial division. [21] [34] [94] Since the peroneal division innervates only the BF-SH, with the remainder of the hamstring muscles innervated by the tibial division, hamstring strength would be normal to near normal. Thus, sciatic neuropathy affecting only the peroneal division may mimic peroneal neuropathy at the knee or at the fibular head.

ELECTROPHYSIOLOGY

Electromyography (EMG) and nerve-conduction studies (NCS) play a vital role in localizing the lesion and in determining severity and prognosis. Evaluation of the sural and superficial peroneal sensory-nerve action potentials (SNAP) are important for documenting whether the lesion is preganglionic or postganglionic, the degree to which tibial and peroneal sensory axons are affected, and the severity of the lesion. The extensor digitorum brevis, the abductor hallucis compound muscle action potentials (CMAP), and the peroneal and tibial *F* waves are useful for defining

*References [2] [13] [21] [25] [27] [29] [33] [34] [40] [55] [80] [84] [86] [89] [90] [94]

621

the distribution of motor abnormalities and the severity of motor axonal degeneration. Contralateral NCS may be helpful for comparison. The saphenous SNAP, tibialis anterior CMAP, and soleus H reflex can be helpful in selected cases. Needle EMG examination should include the peroneal- and tibial-innervated muscles above and below the knee, and several nonsciatic-innervated muscles, including the gluteal muscles, femoral-innervated muscles, and lumbosacral paraspinal muscles.

Somatosensory evoked potentials may occasionally be useful in localizing the lesion.

OTHER DIAGNOSTIC TESTS

Ancillary tests can play a role in confirming or excluding a diagnosis on the basis of the history, examination, and electrodiagnostic testing. Radiologic studies help to evaluate the possibility of a mass lesion or a compressed nerve. MRI provides the best resolution. Recent innovations in which MRI short tau inversion recovery (STIR) sequence has been used have further enhanced the ability to visualize the peripheral nerve (Fig. 3) (Figure Not Available). CT of the sciatic nerve provides excellent visualization of hemorrhage and bony structures. Angiography may be indicated if an arterial aneurysm or iliac artery thrombosis are possible causes.

Laboratory tests can be useful in determining if there are associated medical conditions as a cause of sciatic neuropathy. For example, sedimentation rate and antinuclear antibody are useful to evaluate for vasculitis. Fasting serum glucose and hemoglobin A1C are helpful to rule out diabetes mellitus. Nerve biopsy of the sural or the superficial peroneal sensory nerves is rarely indicated for most causes of sciatic neuropathy, except for the possibility of vasculitis.

DIFFERENTIAL DIAGNOSIS

Lesions of the lumbosacral roots or plexus can mimic sciatic neuropathy. Involvement of sensory or motor fibers outside of the sciatic-nerve distribution places the lesion elsewhere. For example, an L5 or S1 radiculopathy can be distinguished from a sciatic neuropathy by electromyographic abnormalities in the paraspinal muscles, gluteus medius, gluteus maximus, or tensor fascia latae. Abnormalities of the sural or the superficial peroneal sensory responses on NCS would favor sciatic neuropathy over an L5 or S1 radiculopathy.

Bilateral sciatic neuropathy can be difficult to differentiate from polyneuropathy. Careful documentation of sensory and motor deficits can help to differentiate the two. Sensation in the medial foot and lower leg is supplied by the saphenous nerve, which is spared in sciatic neuropathy but often involved in a polyneuropathy. Hamstring muscles are often involved in sciatic neuropathy but only rarely in polyneuropathy.

622

Figure 3. (Figure Not Available) A 29-year-old woman with slowly progressive weakness, muscle atrophy, and numbness in the right sciatic-distribution over five years. A neurologic evaluation for vasculitis or other causes of sciatic neuropathy was negative. MR image scan, including STIR (short tau inversion recovery) sequence, revealed increased signal on STIR sequence and slightly increased diameter of the sciatic nerve without evidence of mass lesion or compression. Neurosurgical exploration was deferred based on the MR image finding. *A*, Axial T1 of the right pelvis: normal appearing sciatic nerve (*arrow*). *B*, Axial STIR of the right pelvis: the sciatic nerve (*arrow*) is increased in signal. A normal sciatic nerve is approximately the same signal intensity of muscle on STIR sequence. *C*, Coronal T1 of the pelvis: normal appearing sciatic nerve (*arrows*). *D*, Coronal STIR of the pelvis: the sciatic nerve (*arrows*) is increased in signal. *E*, Axial T1 of the right mid-thigh: the sciatic nerve is slightly larger in diameter than normal, otherwise normal in appearance. *F*, Axial STIR of the right mid-thigh: the sciatic nerve (*arrow*) is increased in signal. (Courtesy of Kenneth Maravilla, MD and Michel Kliot, MD, University of Washington, Seattle, WA.)

623

Tibial and peroneal mononeuropathies can occur simultaneously and mimic a sciatic neuropathy. Thus, the clinical context in which the nerve injury occurs must be considered when the site of lesion is being determined.

Because the peroneal division is usually more severely affected than the tibial division, a sciatic neuropathy can be difficult to distinguish from a peroneal neuropathy. This difficulty is especially evident when nerve-conduction abnormalities of the tibial or the sural nerve or electromyographic findings in the BF-SH (the only muscle proximal to the knee that is innervated by the peroneal division) are mild.

ORIGINS

The causes of sciatic neuropathies can be categorized into those occurring in the hip (gluteal) or the thigh regions. The majority of sciatic neuropathies occur in the hip, whereas only a minority are in the thigh. ^[94] The causes of sciatic mononeuropathy are numerous (see table).

[9] [13] [40] [55] [78] [84]

Sciatic Neuropathy at the Hip

In our series of 100 patients, ^[94] the most common cause of sciatic neuropathy was total hip arthroplasty. It is the most common neurologic complication of total hip arthroplasty, with frequency ranging from 0.7% to 3.7% of all arthroplasties. * The proximity of the sciatic nerve to the hip joint leaves it vulnerable to injury during surgery. Possible mechanisms for nerve injury include stretching, direct nerve trauma such as from retractors, infarction, hemorrhage, hip dislocation, compression or burns from methylmethacrylate, trauma or entrapment from trochanteric wire,

*References [7] [17] [30] [42] [57] [66] [69] [75] [79] [88] .

624

TABLE 1 -- ORIGINS OF SCIATIC NEUROPATHY**Hip (gluteal) Region**

Hip replacement/surgery

Perioperative

Delayed

Hip dislocation/fracture

Acute

Delayed

Acute, external compression

Coma/drug OD

Coma/ICU

Prolonged sitting

Cardiac surgery

Gluteal compartment syndrome

Gluteal contusion

Gluteal injection

Lithotomy position

Vaginal delivery

Piriformis syndrome

Thigh Region

Femur fracture

Acute, external compression

Posterior thigh compartment syndrome

Entrapment (myofascial band)

Laceration

Hip or Thigh Region

Gunshot wound

Nerve infarction

Vasculitis

Arterial thrombosis

Arterial bypass surgery

Diabetes mellitus

Postradiation therapy

Mass lesion

Benign tumors

Malignant cancers

Endometriosis

Arterial aneurysm

Persistent sciatic artery

Myositis ossificans

Abscess

Idiopathic

Acute/subacute onset

Slowly progressive

osseous tunnel formation, and prosthetic dislocation. † In most cases, the exact mechanism of injury is unknown. ^{[30] [66]} Risk factors include patients who have congenital hip dislocation or dysplasia and patients who have total hip arthroplasty revision. ^[66]

Most cases of sciatic neuropathy associated with hip arthroplasty occur during the perioperative time period; however, some patients suffer

† References [7] [17] [23] [30] [42] [57] [66] [69] [75] [79] [88] [93] .

625

a delayed onset of neuropathy of several years. ^[93] Causes of delayed neuropathy include entrapment from methylmethacrylate, trochanteric wire, osseous tunnel formation, or prosthetic dislocation. ^{[3] [18] [23] [26] [30] [50]} Thus, a history of hip arthroplasty should be sought for anyone suspected of having sciatic neuropathy.

Hip dislocation or fracture are most often caused by motor vehicle accidents and are a frequent cause of sciatic neuropathy. ^{[8] [21] [28] [78] [94]} The most likely mechanism of injury is a stretching of the nerve when the femur is dislocated posteriorly from the hip. Fracture of the posterior acetabular lip can also threaten the sciatic nerve. Occasionally, closed-reduction or open-reduction internal fixation can result in nerve injury. ^{[21] [33]} Delayed entrapment of the sciatic nerve can occur from myositis ossificans ^[23] or ectopic bone formation at the hip leading to an osseous tunnel. ^{[28] [37]}

Prolonged external compression of the sciatic nerve results in nerve injury from direct mechanical disruption of the nerve or ischemia from increased local pressure above capillary perfusion pressure. At least several hours in a supine position (probably at least 8 to 12 hours) with compression at the buttocks are usually required for a sciatic neuropathy to be formed (Yuen, personal communication, 1993). Coma in the setting of drug overdose or in the intensive care unit without frequent repositioning is the usual cause. ^{[53] [71] [78] [94]} Less commonly, gluteal compartment syndrome resulting from gluteal muscle necrosis and edema may be a contributing factor. ^{[68] [71]}

Cardiac surgery has been reported as a cause of sciatic neuropathy. ^{[35] [45]} The mechanism may involve the combination of nerve compression at the level of the buttocks and relative hypotension (and hence reduced capillary perfusion pressure) during surgery. Prolonged sitting position with external compression can rarely lead to sciatic neuropathy, * sometimes as a result of surgical positioning. ^{[36] [56] [78]}

Compartment syndrome from intramuscular hemorrhage into the gluteal muscles have been reported to occur spontaneously in patients undergoing anticoagulation, ^{[41] [62] [78] [94]} with hemophilia ^[72] or from spontaneous arterial rupture in Ehlers-Danlos syndrome. ^[67] Compartment syndrome constitutes a surgical emergency. The sciatic nerve lies deep under the gluteal muscles, and thus is relatively protected from direct trauma. Despite this protection, falls onto the buttocks resulting in gluteal contusion have been reported to cause sciatic neuropathy. ^{[91] [94]} Concomitant gluteal compartment syndrome from muscle necrosis and swelling may play a role in some cases. ^{[68] [91]}

The gluteal muscle is a common site of injection for large volumes of medications. Injection other than in the upper outer quadrant of the gluteal compartment can lead to direct toxic effects of the drug on the nerve. ^{[2] [25] [94]} Sciatic neuropathy has been reported as a delayed complication in patients who have repeated injections and who develop muscle fibrosis compressing the nerve. ^{[48] [64]} Lithotomy position has long been recognized as an infrequent cause of sciatic neuropathy, presumably from a

*References [14] [15] [43] [78] [83] [87] [89] [94] .

626

stretching of the sciatic nerve as the hip is flexed. ^{[10] [33] [46] [63]} Vaginal delivery has been described as a cause of sciatic neuropathy ^[31] ; the mechanism may be from the lithotomy position or from the compression of the sciatic nerve caused by the fetal head in the pelvis near the sciatic notch.

Piriformis syndrome results from entrapment of the sciatic nerve by the piriformis muscle. ^{[1] [6] [29] [47] [52] [76]} It is a controversial entity because it is likely overdiagnosed. ^[39] The sciatic nerve passes under the piriformis muscle as it courses posterior to the hip joint (Fig. 1) . The most prominent symptom is pain in the buttock radiating down the posterior thigh. Weakness, numbness, and paresthesias in the sciatic distribution are generally mild, if present. Important signs include tenderness of the piriformis muscle to palpation and pain with straight leg raising. Stretching of the piriformis muscle against the sciatic nerve by passive internal rotation and adduction of the thigh (Freiberg

sign) has been proposed as a diagnostic maneuver. Active contraction of the piriformis muscle, by active external rotation and abduction of the thigh against resistance (Pace sign), is another proposed diagnostic sign. Hypertrophy of the piriformis muscle has been demonstrated on MRI or CT scans in some cases. The most common inciting factor is blunt trauma to the buttock, such as with a fall. Others have reported exercise, such as with rapid internal rotation of the thigh, as a cause. Normal variations in which the sciatic nerve passes inbetween the tendons or the muscle belly of the piriformis muscle have been reported in as much as 21% of normal cadavers [54] and have been proposed as a predisposing factor leading to compression of the sciatic nerve.

Sciatic Neuropathy at the Thigh

Fracture of the femur can result in stretching and injury of the sciatic nerve. [49] [70] [78] [94] Other acute causes include external compression from thigh tourniquet, [51] [93] or internal compression from posterior thigh compartment syndrome caused by hematomas [94] [95] or edema. [56] Entrapment of the sciatic nerve is rare but has been reported to occur in the thigh from a myofascial band. [5] [74] [85] Laceration of the sciatic nerve has been reported from knife wounds. [70] [90] [93]

Sciatic Neuropathy at the Hip or Thigh

In the early 1900s, gunshot wound was the most common cause of sciatic neuropathy. [9] [27] [55] [70] [80] [90] Unfortunately, gunshot wound is still a common cause in the United States, despite the lack of wartime injuries. [94] The mechanism of nerve injury is most likely from a combination of stretching and percussion injury to the nerve. [60] The nerve is only rarely severed by the bullet.

Nerve infarction has been reported from thromboembolic events associated with vasculitis, arterial bypass surgery, diabetes mellitus, or atherosclerosis

of the iliac artery. [33] [44] [94] Delayed effects of radiation therapy, presumably on the basis of microinfarction of the nerve, may rarely lead to sciatic neuropathy. [94]

Mass lesions can cause compression anywhere along the sciatic nerve. They include benign [58] [73] and malignant [38] [82] tumors (including lymphoma [20] [33] [61]), arterial aneurysm, [11] [59] persistent sciatic artery, [24] endometriosis, [4] [22] [65] [77] myositis ossificans, [32] [37] or abscess. [12]

Rarely, there is no definitive cause to explain some cases of sciatic neuropathy. Some patients develop a chronic, slowly progressive, painless, sciatic neuropathy with no explanation even after surgical exploration. [19] [33] [93] Others develop an acute or subacute sciatic neuropathy with subsequent stabilization or improvement. [93]

PRACTICAL MANAGEMENT

Management of sciatic neuropathy depends on the clinical setting and the suspected cause. The underlying cause of the neuropathy should be treated medically if possible, examples being vasculitis, endometriosis, systemic cancer, or diabetes mellitus. Surgical exploration and decompression may be required when compression of the nerve from mass lesions, (e.g., tumor or hemorrhage), compartment syndrome, or fibrous bands is suspected. [16]

Surgical repair with nerve grafts of the sciatic nerve is generally disappointing. This most likely stems from the long distance of axonal regeneration from the site of lesion to the muscles below the knee. [80]

Weakness from a sciatic neuropathy often leads to foot drop and ankle instability. An ankle-foot orthotic is often helpful if the motor deficit is severe. Dysesthesias are frequent and can be treated symptomatically. Nortriptyline or other tricyclic antidepressants, gabapentin, carbamazepine, and mexilitine may be helpful. Topical medications such as lidocaine or clonidine are being tested and may soon be available. Nerve blocks may also be useful.

There are many case reports of the controversial piriformis syndrome in which physical therapy, steroid injection of the piriformis muscle, and surgical dissection or resection of the muscle have been purported to relieve symptoms. [1] [6] [29] [47] [52] [76]

PROGNOSIS

As with other mononeuropathies, prognosis of sciatic neuropathy depends on its origin etiology and severity. In a study of 52 patients who had acute sciatic neuropathy and removal of the inciting factor (caused by hip replacement, hip dislocation or fractures, gunshot wound, acute external compression, nerve infarction, femur fracture, or gluteal contusion), improvement in strength to Medical Research Council (MRC) grade

628

2 or by at least 2 MRC grades occurred in 30% by 1 year, 50% by 2 years, and 75% by 3 years. ^[93] Factors predictive of good prognosis included the presence of a recordable extensor digitorum brevis CMAP and the absence of ankle paralysis. ^[93]

These findings are similar to those reported in a series of patients who had sciatic neuropathy after total hip arthroplasty. ^[66] Of 52 patients who had sciatic neuropathy, 44% had complete resolution, 44% had mild persistent neurologic deficits, and the remaining 12% had major persistent deficits. The main factor predicting better neurologic outcome was the presence of partial motor function on initial examination.

ACKNOWLEDGMENT

We thank Cynthia So for assistance with Figures 1 and 2 .

References

1. Adams JA: The piriformis syndrome--report of four cases and review of the literature. *S Afr J Surg* 18:13-18, 1980 Citation
2. Ahuja B, Dhamija K: Sciatic neuropathy. *Indian Pediatr* 21:797-801, 1984 Citation
3. Asnis SE, Hanley S, Shelton PD: Sciatic neuropathy secondary to migration of trochanteric wire following total hip arthroplasty. *Clin Orthop* 196:226-228, 1985
4. Baker GS, Parsons WR, Welch JS: Endometriosis within the sheath of the sciatic nerve. Report of two patients with progressive paralysis. *J Neurosurg* 25:652-655, 1966 Citation
5. Banerjee T, Hall CD: Sciatic entrapment neuropathy. Case report. *J Neurosurg* 45:216-217, 1976 Abstract
6. Barton PM: Piriformis syndrome: A rational approach to management. *Pain* 47:345-352, 1991 Abstract
7. Birch R, Wilkinson MC, Vijayan KP, et al: Cement burn of the sciatic nerve. *J Bone Joint Surg* 74B:731-733, 1992 Abstract
8. Brav EA: Traumatic dislocation of the hip: Army experience and results over a twelve-year period. *J Bone Joint Surg* 44A:1115-1134, 1962
9. Bristow WR: Injuries of peripheral nerves in two world wars. *Br J Surg* 34:333-348, 1947
10. Burkhart FL, Daly JW: Sciatic and peroneal nerve injury: A complication of vaginal operations. *Obstet Gynecol* 28:99-102, 1966 Citation
11. Chapman EM, Shaw RS, Kubaik CS: Sciatic pain from arteriosclerotic aneurysm of pelvic arteries. *N Engl J Med* 271:1410-1411, 1964
12. Chen WS: Sciatica due to piriformis pyomyositis. Report of a case. *J Bone Joint Surg* 74A:1546-1548, 1992 Citation
13. Clawson DK, Seddon HJ: The late consequences of sciatic nerve injury. *J Bone Joint Surg* 42A:213-225, 1960
14. Crisci C, Baker MK, Wood MB, et al: Trochanteric sciatic neuropathy. *Neurology* 39:1539-1541, 1989 Abstract
15. Deverell WF, Ferguson JH: An unusual case of sciatic nerve paralysis. *JAMA* 205:699-700, 1968 Citation
16. Dubuisson A, Kline DG: Indications for peripheral nerve and brachial plexus surgery. *Neurol Clin* 10:935-951, 1992 Abstract
17. Edwards BN, Tullos HS, Noble PC: Contributory factors and etiology of sciatic nerve palsy in total hip arthroplasty. *Clin Orthop* 218:136-141, 1987

18. Edwards MS, Barbaro NM, Asher SW, et al: Delayed sciatic palsy after total hip replacement: Case report. *Neurosurgery* 9:61-63, 1981 Abstract
 19. Engstrom JW, Layzer RB, Olney RK, et al: Idiopathic, progressive mononeuropathy in young people. *Arch Neurol* 50:20-23, 1993 Abstract
 - 20.
-
- 629**
- Eusebi V, Bondi A, Cancellieri A, et al: Primary malignant lymphoma of sciatic nerve. Report of a case. *Am J Surg Pathol* 14:881-885, 1990 Abstract
 21. Fassler PR, Swionkowski MF, Kilroy AW, et al: Injury of the sciatic nerve associated with acetabular fracture. *J Bone Joint Surg* 75A:1157-1166, 1993 Abstract
 22. Forrest JS, Brooks DL: Cyclic sciatica of endometriosis. *JAMA* 222:1177-1178, 1972 Citation
 23. Gadelrab RR: Sciatic nerve entrapment in an osseous tunnel as a late complication of fracture dislocation of the hip. *Orthopedics* 13:1262-1264, 1990 Citation
 24. Gasecki AP, Ebers GC, Vellet AD, et al: Sciatic neuropathy associated with persistent sciatic artery. *Arch Neurol* 49:967-968, 1992 Abstract
 25. Gilles FH, Matson DD: Sciatic nerve injury following misplaced gluteal injection. *J Pediatr* 76:247-254, 1970 Citation
 26. Glover MG, Convery FR: Migration of fractured greater trochanteric osteotomy wire with resultant sciatica. A report of two cases. *Orthopedics* 12:743-744, 1989 Citation
 27. Hammond TE: The involvement of the external and internal popliteal nerves in lesions of the sciatic nerve. *BMJ* 1:397, 1918
 28. Hirasawa Y, Oda R, Nakatani K: Sciatic nerve paralysis in posterior dislocation of the hip. A case report. *Clin Orthop* 126:172-175, 1977
 29. Hughes SS, Goldstein MN, Hicks DG, et al: Extrapelvic compression of the sciatic nerve. An unusual cause of pain about the hip: Report of five cases. *J Bone Joint Surg* 74A:1553-1559, 1992 Citation
 30. Johanson NA, Pellicci PM, Tsairis P, et al: Nerve injury in total hip arthroplasty. *Clin Orthop* 179:214-222, 1983
 31. Johnson EW: Sciatic nerve palsy following delivery. *Postgrad Med* 30:495-497, 1961
 32. Jones BV, Ward MW: Myositis ossificans in the biceps femoris muscles causing sciatic nerve palsy. A case report. *J Bone Joint Surg* 62B:506-507, 1980
 33. Jones HR, Gianturco LE, Gross PT, et al: Sciatic neuropathies in childhood: A report of ten cases and review of the literature. *J Child Neurol* 3:193-199, 1988 Abstract
 34. Katirji B, Wilbourn AJ: High sciatic lesion mimicking peroneal neuropathy at the fibular head. *J Neurol Sci* 121:172-175, 1994 Abstract
 35. Kempster P, Gates P, Byrne E, et al: Painful sciatic neuropathy following cardiac surgery. *Aust N Z J Med* 21:732-735, 1991 Abstract
 36. Keykhah MM, Rosenberg H: Bilateral footdrop after craniotomy in the sitting position. *Anesthesiology* 51:163-164, 1979 Citation
 37. Kleiman SG, Stevens J, Kolb L, et al: Late sciatic-nerve palsy following posterior fracture-dislocation of the hip. A case report. *J Bone Joint Surg* 53A:781-782, 1971 Citation
 38. Kleiner JB, Donaldson WF, Curd JG, et al: Extrapelvic causes of lumbosacral radiculopathy. *J Bone Joint Surg* 73:817-821, 1991 Abstract
 39. Kline DG: Comment to "The piriformis muscle syndrome: A simple diagnostic maneuver". *Neurosurgery* 34:514, 1994
 40. Kline DG: Operative management of major nerve lesions of the lower extremity. *Surg Clin North Am* 52:1247-1265, 1972 Citation
 41. Leonard MA: Sciatic nerve paralysis following anticoagulant therapy. *J Bone Joint Surg* 54B:152-153, 1972 Citation
 42. Mallory TH: Sciatic nerve entrapment secondary to trochanteric wiring following total hip arthroplasty. A case report. *Clin Orthop* 180:198-200, 1983
 43. March LM, Francis H, Webb J: Benign joint hypermobility with neuropathies: Documentation and mechanism of median, sciatic, and common peroneal nerve compression. *Clin Rheumatol* 7:35-40, 1988 Abstract

44. Massey EW, Weed T: Sciatic neuropathy with giant-cell arteritis [letter]. *N Engl J Med* 298:917, 1978 **Citation**
45. McManis PG: Sciatic nerve lesions during cardiac surgery. *Neurology* 44:684-687, 1994 **Abstract**
46. McQuarrie HG, Harris JW, Ellsworth HS, et al: Sciatic neuropathy complicating vaginal hysterectomy. *Am J Obstet Gynecol* 113:223-232, 1972 **Citation**
47. Mizuguchi T: Division of the piriformis muscle for the treatment of sciatica. Postlaminectomy syndrome and osteoarthritis of the spine. *Arch Surg* 111:719-722, 1976 **Abstract**
48. Napiontek M, Ruskowski K: Paralytic drop foot and gluteal fibrosis after intramuscular injections. *J Bone Joint Surg* 75B:83-85, 1993 **Abstract**
-

630

49. Neer CS, Grantham SA, Foster RR: Femoral shaft fracture with sciatic nerve palsy. *JAMA* 214:2307-2311, 1970 **Citation**
50. Oleksak M, Edge AJ: Compression of the sciatic nerve by methylmethacrylate cement after total hip replacement. *J Bone Joint Surg* 74B:729-730, 1992 **Abstract**
51. Parks BJ: Postoperative peripheral neuropathies. *Surgery* 74:348-357, 1973 **Citation**
52. Parziale JR, Hudgins TH, Fishman LM: The piriformis syndrome [see comments]. *Am J Orthop* 25:819-823, 1996 **Abstract**
53. Pearce JM: Peripheral nerve lesions in the muscle compartment syndrome [letter]. *BMJ* 280:109-110, 1980
54. Pecina M: Contribution to the etiological explanation of the piriformis syndrome. *Acta Anat* 105:181-187, 1979 **Abstract**
55. Pollock LJ, Davis L: Peripheral nerve injuries: The sciatic nerve. *Am J Surg* 18:176-193, 1932
56. Poppi M, Giuliani G, Gambari PI, et al: A hazard of craniotomy in the sitting position: The posterior compartment syndrome of the thigh. Case report. *J Neurosurg* 71:618-619, 1989 **Abstract**
57. Porter SS, Black DL, Reckling FW, et al: Intraoperative cortical somatosensory evoked potentials for detection of sciatic neuropathy during total hip arthroplasty. *J Clin Anesth* 1:170-176, 1989 **Abstract**
58. Powers SK, Norman D, Edwards MS: Computerized tomography of peripheral nerve lesions. *J Neurosurg* 59:131-136, 1983 **Abstract**
59. Proschek R, Fowles JV, Bruneau L: A case of post-traumatic false aneurysm of the superior gluteal artery with compression of the sciatic nerve. *Can J Surg* 26:554-555, 1983 **Abstract**
60. Puckett WO, Grundfest H, McElroy WD, et al: Damage to peripheral nerves by high velocity missiles without a direct hit. *J Neurosurg* 3:294-305, 1946
61. Purohit DP, Dick DJ, Perry RH, et al: Solitary extranodal lymphoma of sciatic nerve. *J Neurol Sci* 74:23-34, 1986 **Abstract**
62. Rogers L, Wilbourn A, Lesser M, et al: Spontaneous severe sciatic and gluteal mononeuropathies (gluteal compartment syndrome): A peripheral nerve complication of anticoagulation [abstract]. *Ann Neurol* 14:142-143, 1983
63. Romfh JH, Currier RD: Sciatic neuropathy induced by the lithotomy position [letter]. *Arch Neurol* 40:127, 1983 **Citation**
64. Rousseau JJ, Reznik M, LeJeune GN, et al: Sciatic nerve entrapment by pentazocine-induced muscle fibrosis: A case report. *Arch Neurol* 36:723-724, 1979 **Abstract**
65. Salazar-Grueso E, Roos R: Sciatic endometriosis: A treatable sensorimotor mononeuropathy. *Neurology* 36:1360-1363, 1986 **Abstract**
66. Schmalzried TP, Amstutz HC, Dorey FJ: Nerve palsy associated with total hip replacement. Risk factors and prognosis. *J Bone Joint Surg* 73A:1074-1080, 1991 **Abstract**
67. Schmalzried TP, Eckardt JJ: Spontaneous gluteal artery rupture resulting in compartment syndrome and sciatic neuropathy. Report of a case in Ehlers-Danlos syndrome. *Clin Orthop* 275:253-257, 1992

68. Schmalzried TP, Neal WC, Eckardt JJ: Gluteal compartment and crush syndromes. Report of three cases and review of the literature. *Clin Orthop* 277:161-165, 1992
69. Scott RD, Sarokhan AJ, Dalziel R: Total hip and total knee arthroplasty in juvenile rheumatoid arthritis. *Clin Orthop* 182:90-98, 1984
70. Seddon HJ: Lesions of individual nerves: Lower limb. *In Surgical Disorders of the Peripheral Nerves*, ed 2. New York, Churchill Livingstone, 1975, pp 214-229
71. Shields RJ, Root KJ, Wilbourn AJ: Compartment syndromes and compression neuropathies in coma. *Neurology* 36:1370-1374, 1986 **Abstract**
72. Silverstein A: Neuropathy in hemophilia. *JAMA* 190:554-555, 1964
73. Sintzoff SA, Bank WO, Gevenois PA, et al: Simultaneous neurofibroma and schwannoma of the sciatic nerve. *AJNR* 13:1249-1252, 1992
74. Sogaard I: Sciatic nerve entrapment. Case report. *J Neurosurg* 58:275-276, 1983 **Abstract**
75. Solheim LF, Hagen R: Femoral and sciatic neuropathies after total hip arthroplasty. *Acta Orthop Scand* 51:531-534, 1980 **Abstract**
76. Solheim LF, Siewers P, Paus B: The piriformis muscle syndrome. Sciatic nerve entrapment treated with section of the piriformis muscle. *Acta Orthop Scand* 52:73-75, 1981 **Abstract**
- 77.

631

- Stewart J, Murphy G, Wee R: Sciatic nerve palsy due to endometriosis [abstract]. *Can J Neurol Sci* 8:202, 1981
78. Stewart JD, Angus E, Gendron D: Sciatic neuropathies. *BMJ* 287:1108-1109, 1983
79. Stone RG, Weeks LE, Hajdu M, et al: Evaluation of sciatic nerve compromise during total hip arthroplasty. *Clin Orthop* 201:26-31, 1985
80. Sunderland S: Sciatic, tibial and common peroneal nerve lesions. *In Nerves and Nerve Injuries*, ed 2. Edinburgh, Churchill Livingstone, 1978, pp 967-991
81. Sunderland S: The relative susceptibility to injury of the medial and lateral popliteal divisions of the sciatic nerve. *Br J Surg* 41:300-302, 1953
82. Thomas JE, Piegras DG, Scheithauer B, et al: Neurogenic tumors of the sciatic nerve. A clinicopathologic study of 35 cases. *Mayo Clin Proc* 58:640-647, 1983 **Abstract**
83. Tyrrell PJ, Feher MD, Rossor MN: Sciatic nerve damage due to toilet seat entrapment: Another Saturday night palsy [letter]. *J Neurol Neurosurg Psychiatry* 52:1113-1115, 1989 **Citation**
84. Van Langenhove M, Pollefliet A, Vanderstraeten G: A retrospective electrodiagnostic evaluation of footdrop in 303 patients. *Electromyogr Clin Neurophysiol* 29:145-152, 1989 **Abstract**
85. Venna N, Bielawski M, Spatz EM: Sciatic nerve entrapment in a child. Case report. *J Neurosurg* 75:652-654, 1991 **Abstract**
86. Villarejo FJ, Pascual AM: Injection injury of the sciatic nerve (370 cases). *Childs Nerv Syst* 9:229-232, 1993 **Abstract**
87. Vogel CM, Albin R, Alberts JW: Lotus footdrop: Sciatic neuropathy in the thigh. *Neurology* 41:605-606, 1991 **Citation**
88. Weber ER, Daube JR, Coventry MB: Peripheral neuropathies associated with total hip arthroplasty. *J Bone Joint Surg* 58A:66-69, 1976 **Abstract**
89. Wilbourn A, Mitsumoto H: Proximal sciatic neuropathies caused by prolonged sitting [abstract]. *Neurology* 38:400, 1988
90. Wilson SAK: Neuritic lesions of individual peripheral nerves: Great sciatic nerve. *In Neurology*. London, Edward Arnold & Co, 1940, pp 344-363
91. Yoshioka H: Gluteal compartment syndrome. A report of 4 cases. *Acta Orthop Scand* 63:347-349, 1992 **Abstract**
92. Yuen EC, Olney RK, So YT: Sciatic neuropathy: Reply [letter]. *Neurology* 45:1430, 1995 **Abstract**
93. Yuen EC, Olney RK, So YT: Sciatic neuropathy: Clinical and prognostic features in 73 patients. *Neurology* 44:1669-1674, 1994 **Abstract**

94. Yuen EC, So YT, Olney RK: The electrophysiologic features of sciatic neuropathy in 100 patients. *Muscle Nerve* 18:414-420, 1995 Abstract

95. Zimmerman JE, Afshar F, Friedman W, et al: Posterior compartment syndrome of the thigh with a sciatic palsy. *J Neurosurg* 46:369-372, 1977 Citation

Copyright © 2011 Elsevier Inc. All rights reserved. - www.mdconsult.com

Bookmark URL: </das/clinics/view/0/N/10838202?ja=147693&PAGE=1.html&issn=0733-8619&source=MI>